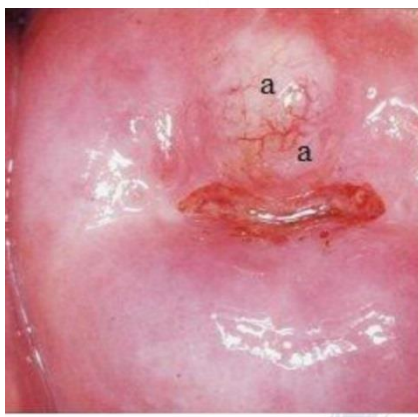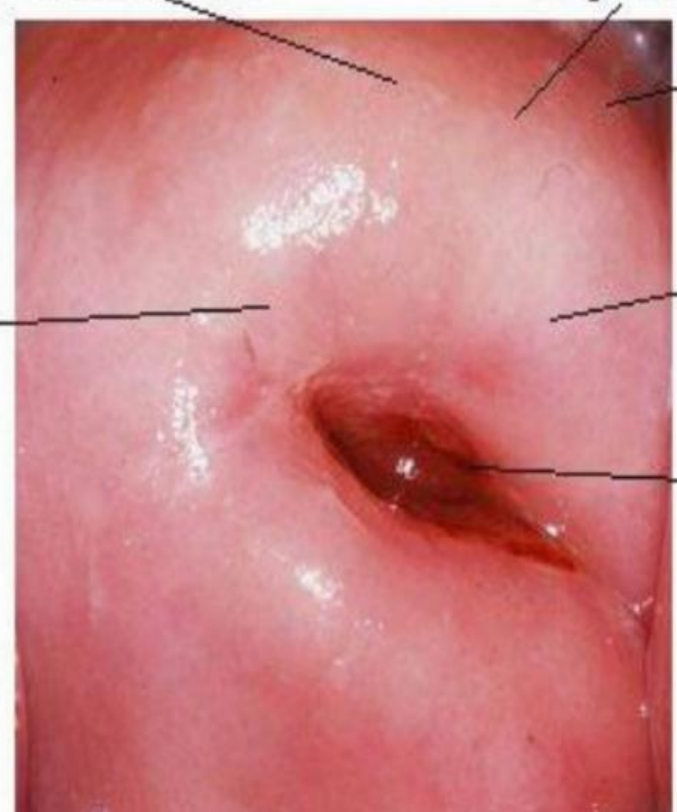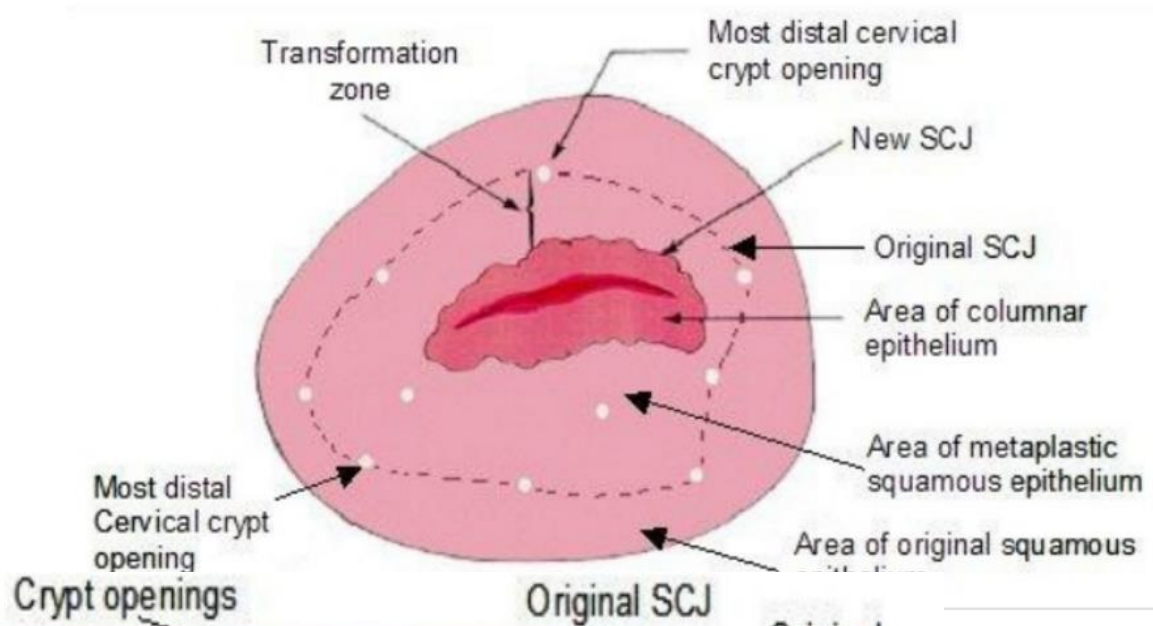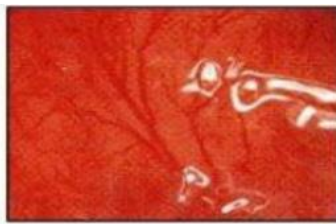
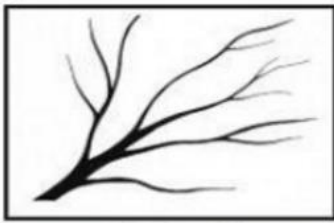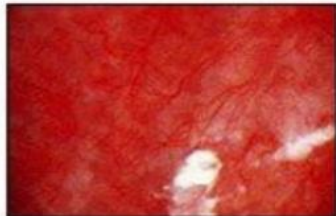
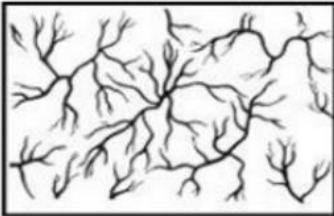


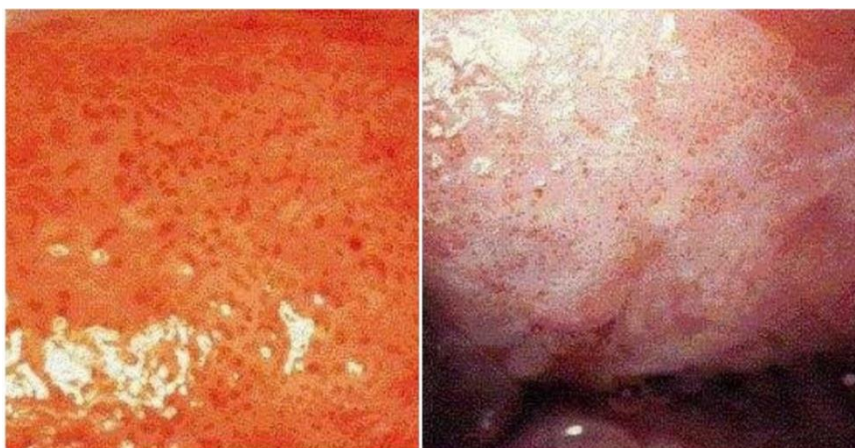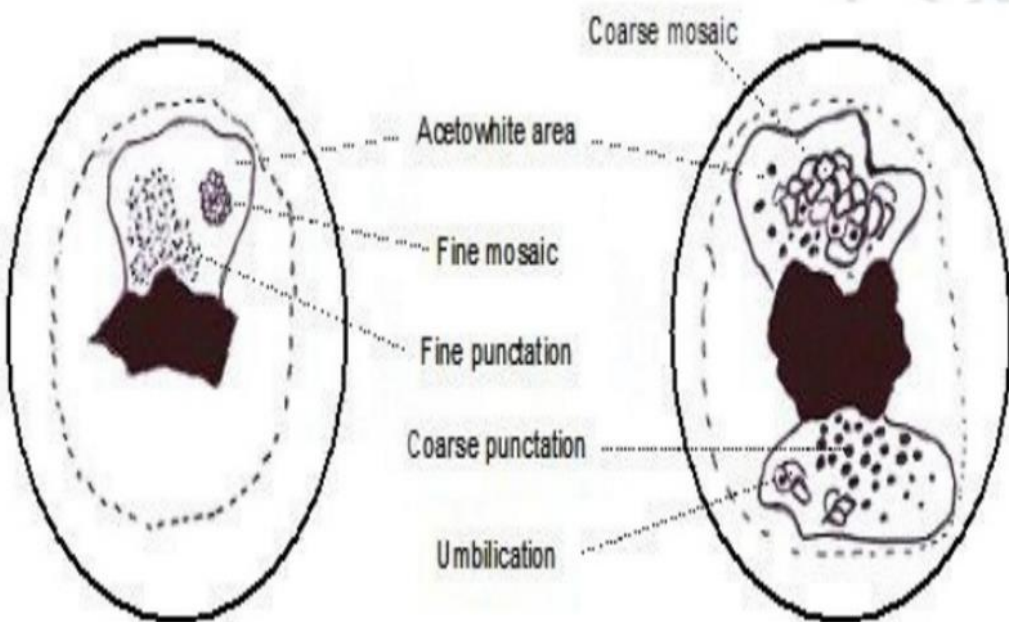
Nabothian cyst with regularly branching tree like vessels



Long, regular branching vascular tree with gradual decrease in calibre



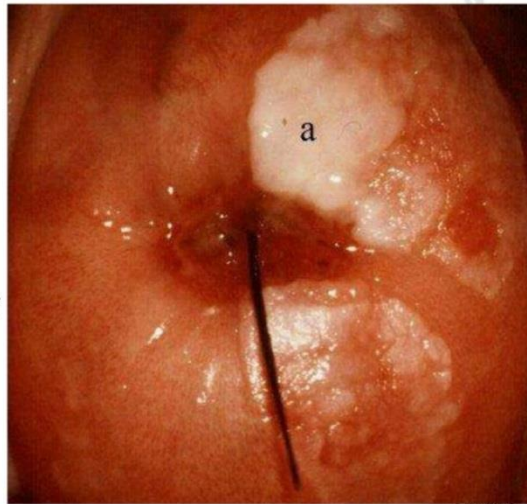
Blood vessels showing regular branching



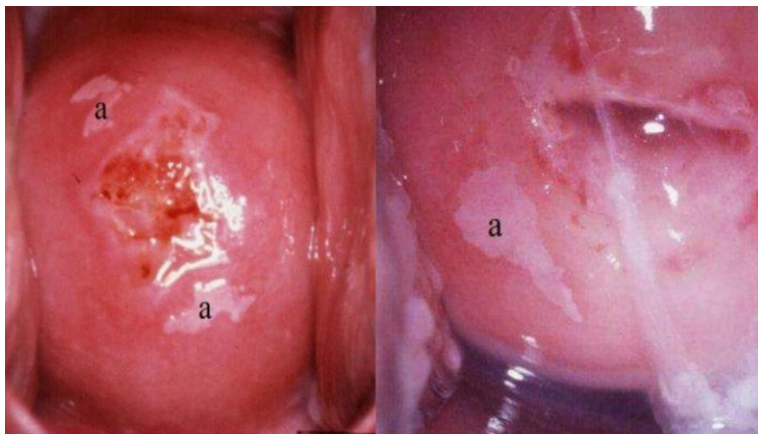
Coarse punctation before & after application of acetic acid

Leukoplakia

- Usually benign
- May obscure an underlying neoplasia
- Therefore, all patches observed before application of acetic acid must be biopsied

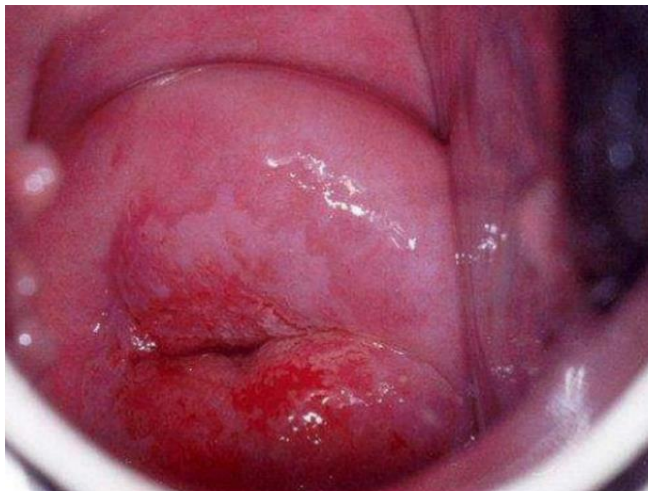

Hyperkeratosis (Leukoplakia)

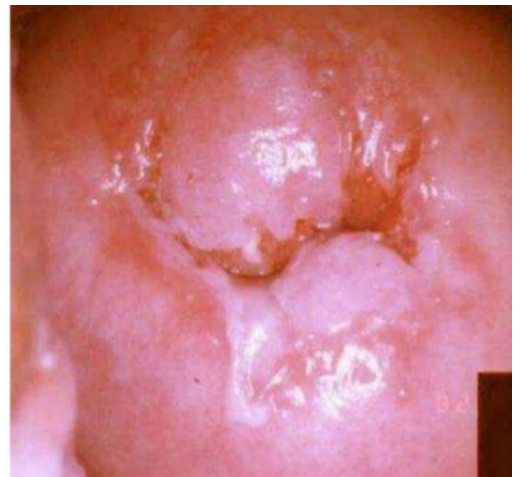

condyloma

low-grade lesion

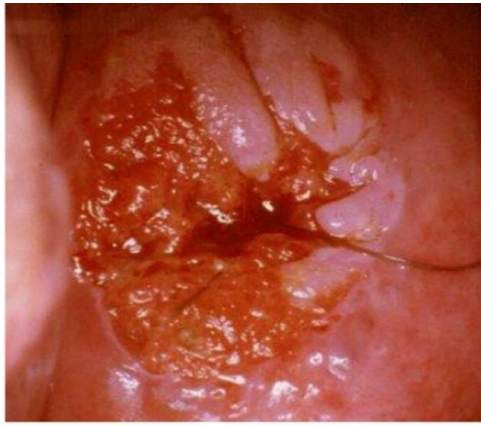


Thin acetowhite lesion with geographic margins in the upper lip. Histology indicated CIN 1

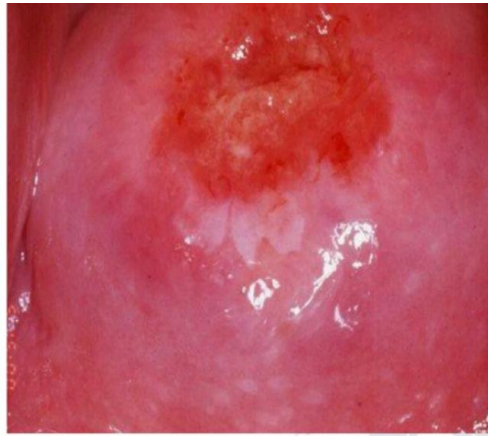

Moderately dense acetowhite lesions with irregular margins in the anterior & posterior lips (CIN 1)

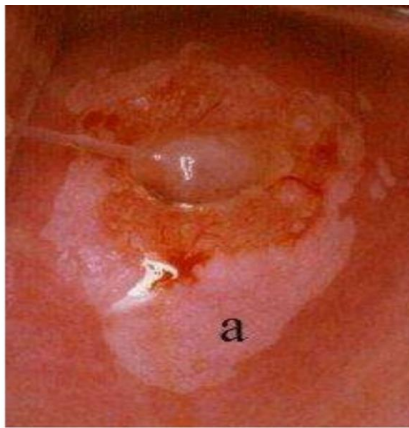




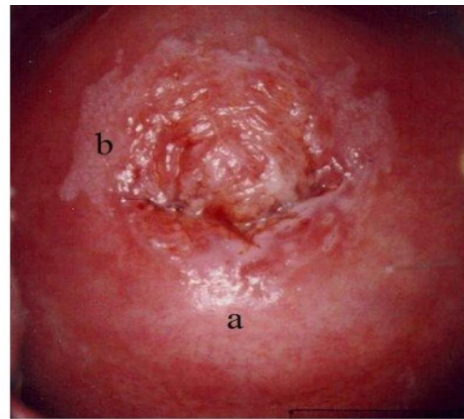
Moderately dense acetowhite lesions with well defined margins & coarse punctations in the anterior lip & in 3 o'clock position (CIN 2 lesion)



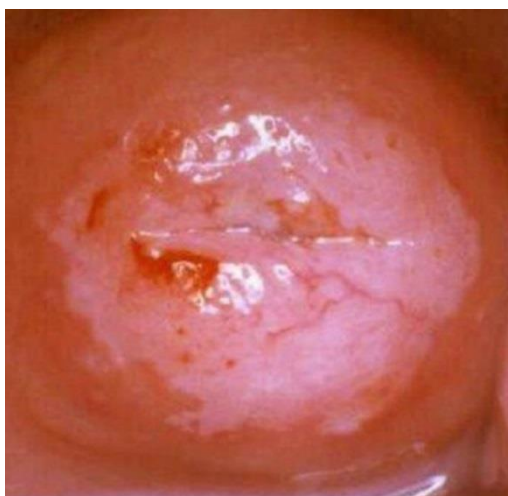Dense well defined acetowhite area with regular margins & coarse mosaic (CIN 2 lesion)



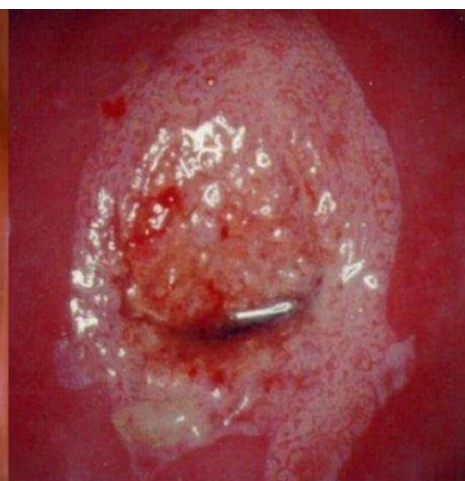A dense acetowhite lesion with varying colour intensity & coarse mosaics (a) in a CIN 2 lesion



Acetowhite lesions with coarse punctation (a) & mosaics (b) in a CIN 2 lesion

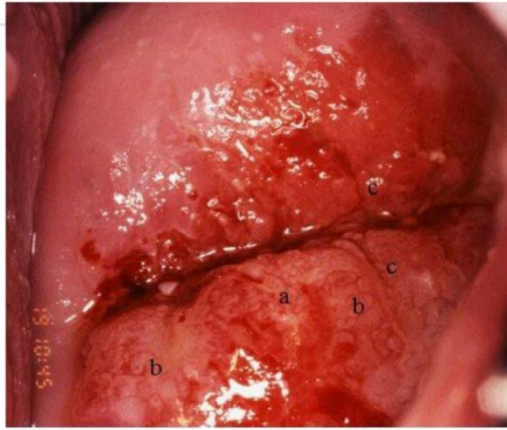

A circumoral dense opaque acetowhite area with coarse mosaics (CIN 3 lesion)

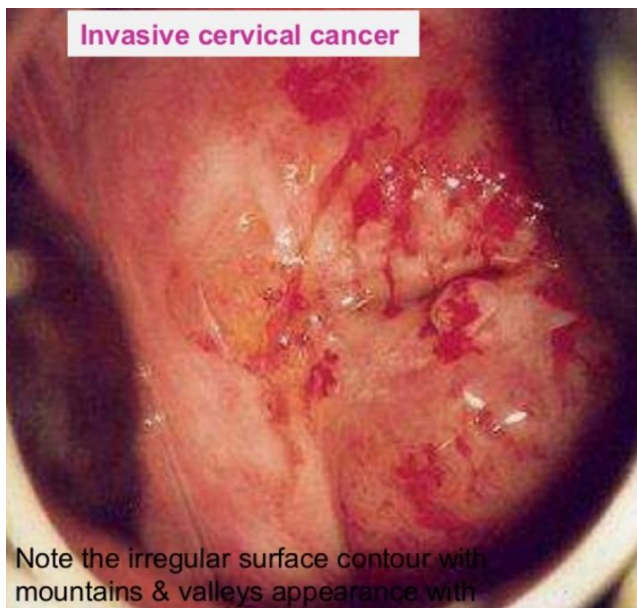


A dense acetowhite lesion with regular margin & coarse, irregular punctation in a CIN 3 lesion

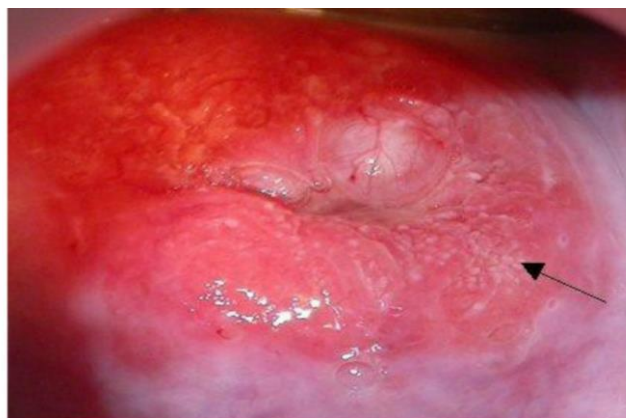



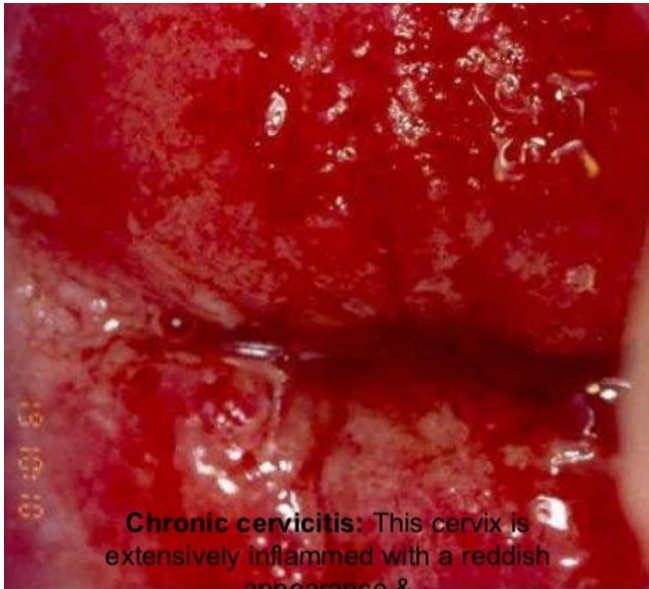Early invasive cancer: note the raised irregular mosaics with umbilication (a), breaking mosaics (b), surface irregularity & the atypical vessels after the application of 5% AA



Note the irregular surface contour with mountains & valleys appearance with atypical blood vessels in the dense acetowhite area



Adenocarcinoma in situ: The tips of some of the columnar villi turn densely white compared to the surrounding columnar villi after the application of acetic acid (arrow). The nabothian cysts turn white after the application of AA



Chronic cervicitis: This cervix is extensively inflamed with a reddish appearance & bleeding on touch, there are ill-defined, patchy acetowhite areas scattered all over the cervix after the application of AA

